

Patient Name: PARVIN, MARY JEAN
Unit No: M053082

<u>EXAM#</u>	<u>TYPE/EXAM</u>	<u>RESULT</u>
001118231	CT/ABDOMEN & PELVIS W/O CONTRAS	

History: Renal failure.

Comparison: Renal ultrasound 5/17/2012.

Technique: Without intravenous contrast, CT imaging of the abdomen and pelvis was performed with axial and coronal reconstructions provided.

Findings: There are small bilateral pleural effusions and atelectasis at the lung bases. There is a small hiatal hernia present. Ventral hernia upper abdomen wall contains omental fat only.

Unenhanced liver and spleen are homogeneous. Minimal free fluid surrounds the liver. Unenhanced adrenal and pancreatic morphology is unremarkable. Kidneys are free of obstruction with vascular calcifications noted. Gallbladder is present.

There is generalized body wall and less so omental and mesenteric as well as presacral edema.

The bowel is free of dilatation or wall thickening. Visceral vascular calcifications are noted throughout. Foley catheter lies within the bladder.

Impression: Pleural effusions with minimal ascites and body wall, omental, mesenteric and presacral edema suggest anasarca.

Atrophic kidneys with vascular calcifications but no evidence of obstruction.

Small hiatal and ventral abdominal wall hernias.

D/T: GWR/

Date Dictated: 05/19/2012 13:03:11
Date Transcribed: 05/19/2012 12:59:23
Doc ID: 249375
Job ID: 343901

PAGE 1

Signed Report

(CONTINUED)

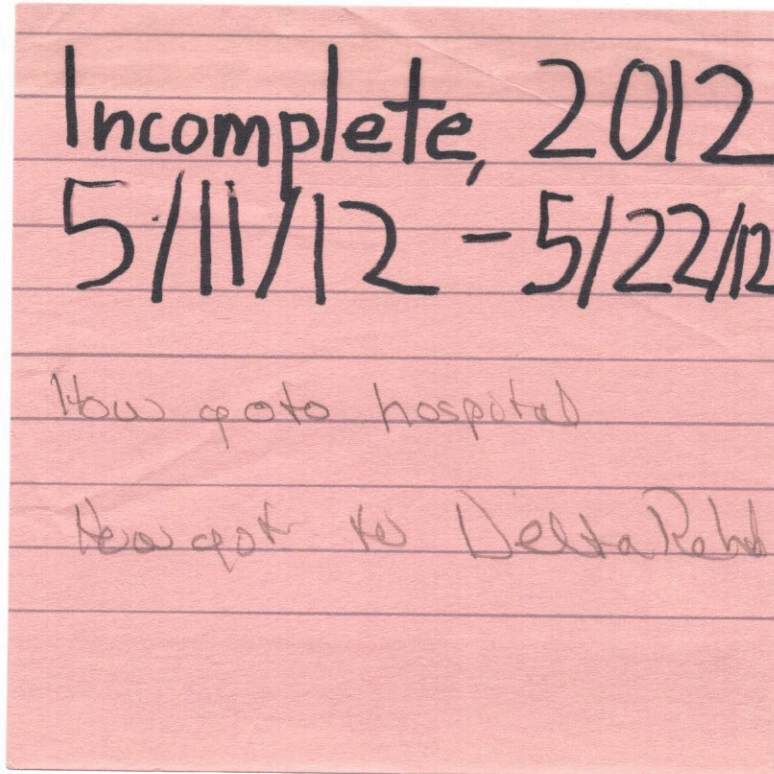
Name: PARVIN, MARY JEAN
Phys: Multani, Kuljeet K MD - HOSP
DOB: 03/16/1943 Age: 69 Sex: F
Acct No: V023586118 Loc: 377 A
Exam Date: 05/19/2012 Status: DIS IN
Radiology No: 00003311

Patient Name: PARVIN, MARY JEAN
Unit No: M053082

<u>EXAM#</u>	<u>TYPE/EXAM</u>	<u>RESULT</u>
001118231	CT/ABDOMEN & PELVIS W/O CONTRAS	
<Continued>		

This document was electronically signed by Grant W. Rogero, M.D. on
05/19/2012 13:03:11.

** REPORT SIGNED IN OTHER VENDOR SYSTEM 05/19/2012 **
Reported By: ROGERO, GRANT W MD



Incomplete, 2012
5/11/12 - 5/22/12
How go to hospital
New go to Delta Rehab

CC: Freund, Edmund MD-Mills; Multani, Kuljeet K MD - HOSP

Technologist: MARCIASINI, SUZANNE
Transcribed Date/Time: 05/19/2012 (1304)
Transcriptionist: EWS
Printed Date/Time: 06/26/2012 (0002)

PAGE 2

Signed Report

Name: PARVIN, MARY JEAN
Phys: Multani, Kuljeet K MD - HOSP
DOB: 03/16/1943 Age: 69 Sex: F
Acct No: V023586118 Loc: 377 A
Exam Date: 05/19/2012 Status: DIS IN
Radiology No: 00003311